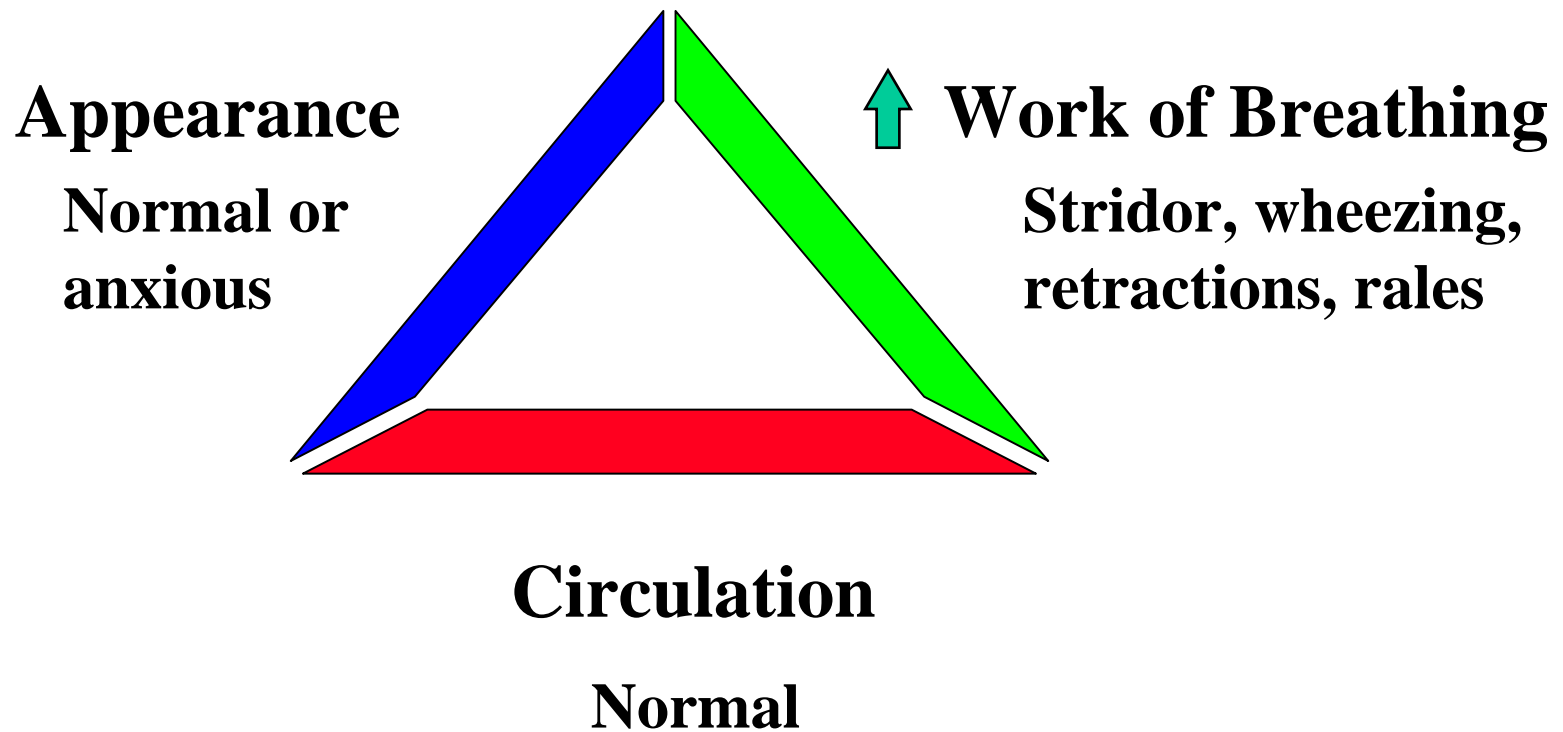


Respiratory Emergencies

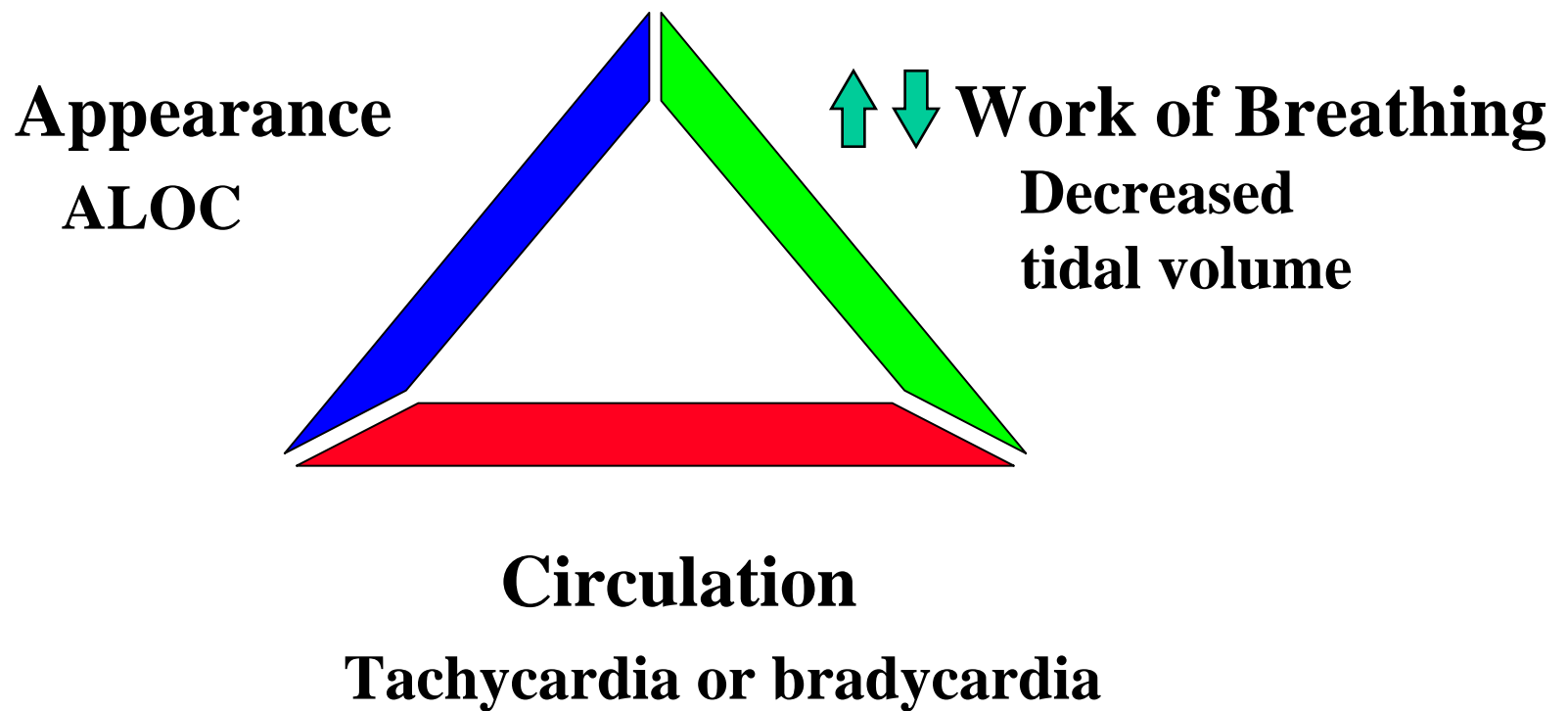
Objectives

- Recognize the child in respiratory distress or failure
- Outline the categories of respiratory conditions and how they differ on presentation
- Discuss the initial management of children with different causes of acute respiratory distress

Rapid Assessment of Respiratory Distress



Rapid Assessment of Respiratory Failure



Categorization of Respiratory Emergencies

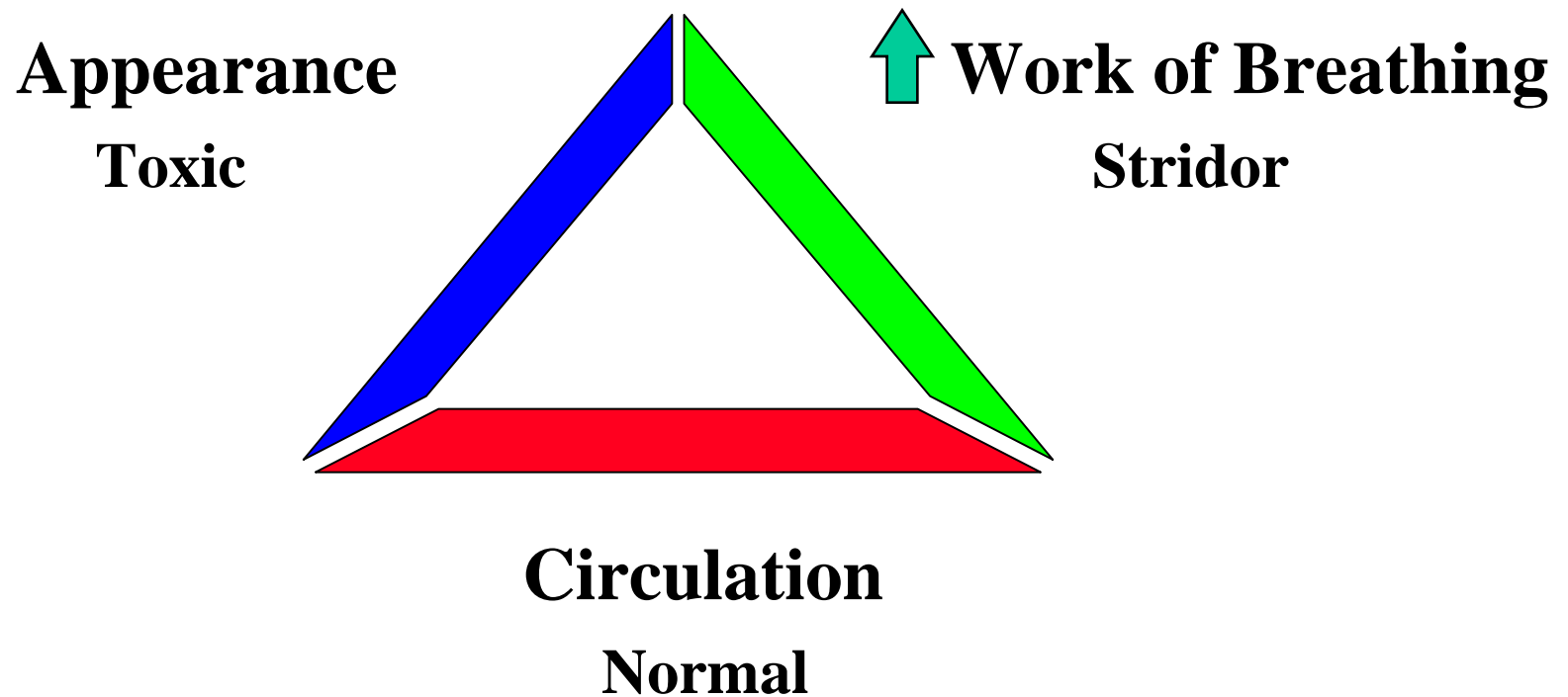
- Airway Obstruction:
 - Upper - Stridor
 - Lower - Wheezing
- Alveolar or interstitial conditions
 - Rales

Case: 6 year old male

- Sudden onset of high fever, sore throat and drooling -doesn't want to lie down
- Toxic appearing
- *Vital signs*: HR 140, RR 30, T40.2°C, O₂ sat. 96%, weight 25 kg

What are your assessment and differential diagnosis for this patient?

Case Discussion: Assessment - Upper Airway Obstruction



Case Discussion: Differential Diagnosis

- Epiglottitis
- Croup
- Bacterial tracheitis
- Retropharyngeal abscess
- Peritonsillar abscess
- Foreign body obstruction

Croup versus Epiglottitis

<u>Clinical Feature</u>	<u>Epiglottitis</u>	<u>Croup</u>
Stridor	+	+
Voice alteration	Muffled	Hoarse
Dyshagia	+	-
Postural preference	+	±
Barky cough	-	+++
Fever	+++	±
Toxicity	++	-

What are your assessment and management priorities now?

Case Discussion : Assessment - Epiglottitis

- Upper airway emergency
- Occurs at any time of year in any age group
- Has become less common with increasing use of *Haemophilus influenzae* vaccine

Case Progression

- Child remained in mother's arms
- Consultants contacted immediately:
 - **Evaluated by surgical specialist and anesthesiologist**
- Airway management in operating room
- Intubation performed, cultures taken and antibiotics started

Case: 18 month old female

- Runny nose, cough and fever for 2 days
- Progressing to barking cough with high-pitched "noise" with every breath
- Assessment Triangle shows:
 - **Appearance - anxious and alert**
 - **Work of Breathing - increased, stridor**
 - **Circulation - normal**

Case Progression

- Alert, in moderate respiratory distress, significant inspiratory stridor at rest
- *Vital signs:* HR 130, RR 42, T 38.8° C, O₂ sat. 98%, weight 12 kg

What are your assessment and management priorities for this patient?

Case Discussion: Assessment - Croup (Laryngotracheobronchitis)

- Upper airway obstruction
- Most common infectious cause of upper airway obstruction
 - **unusual cause of stridor in children <6 months and >6 years**
- Seasonal - late fall and early winter

Case Discussion: Signs and Symptoms, Mild

- 1-3 day history of URI
- Barking cough (94%)
- Fever (low grade usually)
- Tachypnea
- Stridor (58%)
- Retractions/wheezing

Case Discussion: Signs and Symptoms, Severe

- Agitation
- Lethargy
- Progressive tachycardia and tachypnea
- Hypoxia (cyanosis)
- Decrease in tidal volume
- Apnea

Case Discussion: Emergency Department Management

Options

- Cool mist (+/- oxygen)
- Aerosolized (L-) epinephrine/racemic epinephrine
- Corticosteroids
 - **inhaled, oral, parenteral**
- Airway management

Case Progression

- Child placed on mother's lap in treatment room
- Cool mist therapy delivered by mother
- Aerosolized epinephrine given via nebulizer

Case Discussion: Aerosolized Epinephrine

- Racemic mixture
 - **Dose: 0.5 mL of 2.25% Racemic epinephrine in 4.5 mL normal saline**
- L-epinephrine
 - **Dose: 5 ml of the 1:1,000 solution prediluted with normal saline**
- Observe patient in ED for 2-3 hours then discharge as appropriate

Case Discussion: Corticosteroids

- Anti-inflammatory
- Clinical effects within 3 to 4 hours
- Long biologic half-life (36 to 54 hours)
- Improvement with dexamethasone at 24 hours which may reduce need for hospitalization
- Nebulized budesonide may reduce need for hospitalization

Case Progression

- Cool mist, aerosolized epinephrine and dexamethasone (0.6 mg/kg PO) given
- Continues to have inspiratory stridor when agitated and continues to have barky cough

Should this child be admitted for further management?

Admission Criteria

- Stridor at rest after aerosolized epinephrine, corticosteroids and observation for 3 hours
- Respiratory failure requiring airway management
- Requires oxygen to maintain O₂ sat >95%
- Consider if child is less than 6 months of age

Case Progression

- Observed for 3 hours and child continues to improve with disappearance of stridor
- Barky cough persists
- Feeding well
- Discharged with explicit home care instructions

Case : 3 year old female

- History of sudden onset of cough and choking while eating peanuts - paramedics transport to ED
- Assessment Triangle shows:
 - **Appearance - anxious**
 - **Work of Breathing - retractions**
 - **Circulation - normal**

Case Progression

- Physical exam in ED shows patient in mild respiratory distress with unilateral wheezing
- *Vital signs*: HR 120, RR 42, T 37.8 °C, O₂ sat. 92%, weight 14 kg

What is your diagnosis?

Case Discussion: Foreign Body Aspiration

- Often occurs in children <5 years of age
- Common offending agents: foods and home items



Foreign Body Aspiration: Management Priorities

- Incomplete obstruction; alert and breathing
 - **provide supplemental oxygen**
 - **allow position of comfort**
 - **immediate consultation with surgical specialist and airway evaluation and removal of FB in the operating room**

Foreign Body Aspiration: Complete Obstruction

- Attempt ventilation, no chest rise
 - **<1 year: 5 back blows then 5 chest thrusts;**
>1 year: 5 abdominal thrusts
- If unsuccessful:
 - **perform direct laryngoscopy**
 - **immediate surgical consultation**
 - **attempt vigorous BVM ventilation, intubation, or cricothyrotomy**

Case Progression

- Child taken to operating room
- A peanut was removed from the main stem bronchus

Case: 10-year-old Boy

- With a history of asthma has been wheezing for 8 hours
- Assessment Triangle shows:
 - Appearance - anxious
 - Work of breathing - increased with marked tachypnea and retractions
 - Circulation - normal

Case Progression

- Patient alert and anxious, in moderate respiratory distress with retractions and bilateral wheezing
- Vital signs
 - HR - 110
 - RR - 36
 - O₂ sat - 88%
 - Weight - 33 Kg

Case Discussion

Assessment - Asthma

- Lower airway obstruction
 - Intermittent, partially or completely reversible obstructive disease
- Multifactorial precipitants
- Pathogenesis: inflammation - bronchospasm with increased mucus production and airway edema

Case Discussion: Important Historical Factors

- Frequency and severity
 - ED visits, ICU admissions, intubation, corticosteroid treatment, medications
- Age at first onset
- Other atopic features
- Underlying cardiopulmonary disease

Estimation of the Severity by Auscultation

- Minimal : prolonged expiration
- Mild : end-expiratory wheeze only
- Moderate : expiratory and inspiratory wheezing
- Marked : minimal wheezing, inaudible air entry or exit

Diagnostic Evaluation of Severity

- Peak flow meter useful in children who are capable of using it
- Pulse oximetry:
 - May see initial drop in O₂ sat after treatment begins
 - Arterial blood gases not usually useful
- Chest X-ray: not routinely indicated

Asthma: ED Management

- Oxygen
- Fluid resuscitation (oral or iv)
- Nebulized β 2-agonist bronchodilators
- Epinephrine or terbutaline
- Ipratropium bromide
- Corticosteroids
- Rapid sequence intubation for respiratory failure

Case discussion:

Treatment options

- β_2 -agonists (albuterol , ventolin)
 - 2.5 to 5 mg nebulized every 20 min
 - May give more frequently if required
 - MDI with spacer - 4 to 8 puffs every 20 min.
- Ipratropium bromide
 - 0.25 mg by nebulizer

Case Discussion: Treatment Options

- Corticosteroids
 - Dosage: methylprednisolone (iv) or prednisone (PO)
 - 1 to 2 mg/kg
 - Maximum: 60 mg/dose
 - Continue oral prednisone for 3 to 5 days
- Epinephrine 1 : 1000
 - 0.01 mL/kg subcutaneously
 - If severe disease or difficulty delivering inhalers

Other Treatment Modalities

- Magnesium sulfate
- Intravenous β_2 -agonists

Case Progression

- β_2 -agonist given with minimal improvement
- Corticosteroids given after initial assessment
- Peak flow remains at 100; O₂ sat. 90%
- Child admitted for continuous albuteral and inpatient management

Asthma admission Criteria

- Status asthmaticus
- Progressive respiratory distress or failure
- History of severe, poorly responsive attacks
- PEFr persisting at less than 70% in cooperative child

Case: 8 week o;d Girl

- Staccato-like cough for 2 days
- Assessment Triangle shows:
 - Appearance - anxious and alert
 - Work of breathing - tachypnea and mild intercostal retractions
 - Circulation - normal

Case Progression

- Additional history revealed conjunctivitis at 10 days of age - treated with drops
- Rales are noted in bilateral lung fields
- Vital signs
 - HR 146
 - RR 68
 - T 38
 - O₂ sat 92%
 - weight 4 Kg

What are your assessment and management priorities?

Case Discussion:

Assessment - Pneumonia

- Fever, tachypnea and cough constitute cardinal triad
- Rales, decreased breath sounds , but there mat be limited findings
- May present with complaint of abdominal pain
- Infants with cough and wheeze - consider Bronchiolitis

Bronchiolitis

- Inflammatory disease
- Viral etiology
- Management
 - Supportive - oxygen and hydration
 - Steroids and bronchodilators - probably not effective
 - Antibiotics - not indicated

Pneumonia Admission Criteria

- History of apnea
- Respiratory distress
- Hypoxia or cyanosis
- Toxic appearance
- Dehydration
- Immune deficiency or comorbid disease
- Parental factors

Conclusions

- Recognition of children in respiratory distress or failure discussed
- Cases presented to illustrate the difference between upper and lower airway obstruction
- Stepwise management of these disorders with continual reassessment of the patient to evaluate response to therapy

Case Discussion

Pneumonia - ED management

- Supplemental oxygen
- Chest X-ray